



Investigation of wound healing activity of *Malvastrum tricuspidatum* syn *Malvastrum coromandelianum* on experimental animals

N. K. Gangrade*, R.V. Sheorey, H. Rawal and S. Chouhan
Central India Institute of Pharmacy, Indore, (M.P.) - India

Abstract

Effects of topical administration of ethanolic extract of *Malvastrum Tricuspidatum* ointment was studied respectively on two types of wound models in wistar rats, (i) the incision and (ii) the dead space wound model. The ointment of the ethanolic extract of *Malvastrum Tricuspidatum* produced significant response in both of the wound types tested. In the incision model the extract treated wounds were found to epithelialise faster and the rate of wound contraction was higher, as compared to control wounds. The extract facilitates the healing process as evidenced by increase in the tensile strength in the incision model.

Key-Words: Wound healing, *Malvastrum coromandelianum*, Extracts

Introduction

Malvastrum tricuspidatum is a weed of waste places and plantations and found at low altitudes, mainly in areas with seasonal rainfall. The leaves contains malvastrone. The aerial parts contain β -phenylethylamine, dotriacontane, dotriacontanol, β -sitosterol, stigmasterol, campesterol, lutein, N-methyl- β -phenylethylamine and unidentified indole alkaloid.^[1] Palmitic acid, palmitoleic acid, stearic acid, oleic acid, linoleic acid, malvalic acid and sterculic acid.^[2] Pharmacological studies have confirmed that *Malvastrum tricuspidatum* exhibit a broad range of biological effect such as Anti-inflammatory activity, Antipyretic activity, Analgesic activity^[3], Antibacterial activity^[4], Hypoglycemic activity. In West Indies plant is considered to be emollient, resolvent. The leaves are applied to inflamed sores^[5] and plant decoction is given in dysentery. Flowers used in cough, chest and lung diseases.^[6] However, there were no reports on wound healing activity of this plant. Hence, the present study was made to evaluate the wound healing potential.

* Corresponding Author

E-Mail: neel.gangrade@outlook.com

Material and Methods

Plant extract and standard used

The dried coarsely powdered leaves were extracted with petroleum ether, for 48 hours to remove fatty matter. The defatted marc was then subjected to soxhlet extraction with 95% ethanol for 8 hr. The total alcoholic extract was concentrated using rotary evaporator.^[7]

Preparations of dosage forms

Dosage forms of individual drugs were prepared as per following procedures

Preparation of suspension of aqueous and ethanolic extracts for topical application

Suspension of aqueous and alcohol extract of *Malvastrum tricuspidatum* were prepared by triturating it in glass mortar with gradually addition of normal saline solution (0.9 %) to make 10 %w/v.

Standard used

Povidone-iodine ointment USP (5% w/w, available iodine – 0.5%w/w), Om Biomedic Pvt. Ltd. Marketed by Pharma Corp. Inc. Limited.

Animal Used

Wistar rats weighing between 150-200 g of either sex were used. Animals were placed randomly in polypropylene cages (five per cage) with husk as bedding. Standard laboratory condition of temperature $25 \pm 2^{\circ}\text{C}$, relative humidity $55 \pm 5\%$ and 12 hr/12 hr light/dark cycle were maintained throughout the experiment. Animals had free access of water filtered through Aquaguard and food.^[8]

Wound Models

Incision wound model: Wistar rats of either sex weighing 150-200 g were procured and maintained at standard housing conditions. The animals were randomly divided into four groups of five rats each. Under ketamine-xylazine (ketamine 60 mg/kg and xylazine 5 mg/kg i.p.) anesthesia, 6 cm long paravertebral incisions were made through the full thickness of skin on the left side of the vertebral column of each group of rats. All the groups were treated as per the treatment schedule. The wounds were closed with sutures of 1 cm apart. The sutures were removed on the 9th post wound day. The skin breaking strength of the incision wounds was measured on the 10th day.^[9]

Tensiometer and determination of tensile strength

Tensiometer consisted of a 6×12 inch wooden board with one arm 4 inch long, fixed on each side of the possible longest distance of the board. The board was placed at the edge of a table. A pulley with bearing was mounted on the top of one arm. An alligator clamp with 1 cm width was tied on the tip of another arm by a fishing line (20 lb test monofilament) in such a way that the clamp could reach the middle of the board. Another alligator clamp was tied on a longer fishing line with 1-l polyethylene bottle on the other end. One day before performing the experiment (measurement of tensile strength) the sutures were removed from the stitched wounds of rats after recovery and tensile strength were measured as follows.

On the 9th day the sutures were removed and the tensile strength was measured on 10th day. For measuring the tensile strength the rats were again anaesthetized and each rat was placed on a stack of towels on the middle of the board. The amount of the towels could be adjusted in such a way so that the wound were on the same level as the tips of the arms. The clamps were then carefully clamped on the skin of the opposite edges of the wound at a distance of 0.5 cm away from the wound. The longer pieces of the fishing line were placed on the pulley and finally to the polyethylene bottle. The position of the board was adjusted so that the bottle receives a rapid and constant rate of water from a large reservoir, until the wound began to open. The amount of water in the polyethylene bag were weighed and equated as the tensile strength of the wound. The tensile strength induced by the extract and by Povidone-iodine ointment treated wounds was compared with the control.^[10,11]

Histopathological study

The multiple sections were studied in histopathological examination of the tissues of the incision wound skin

treated with the extract 5 % w/w povidone-iodine ointment (standard), 5% w/v ethanolic extract of *Malvastrum tricuspidatum* and 10 % w/v ethanolic extract of *Malvastrum tricuspidatum*, and compared with simple saline (control) and treated group.^[12]

Preparation of histological sections

Thin sections of skin were taken (1x1x5 mm) for examination by sterilized scissor and washed with normal saline in order to remove blood from the tissue and further processed by following steps:

Histopathological Procedures

Fixation

In order to preserve tissues and prevent structural change or breakdown of the components of the tissues, it was fixed in 10 % formalin solution.

Embedding

Paraffin wax, with a melting point of about 56 °C was used. Prior to infiltration of the tissue with molten wax, all the water from the tissue were removed by absolute alcohol (dehydration) and alcohol were removed by using organic solvent i.e. xylene.

Microtomy

Sections of the tissue embedded in the wax block were cut on microtome, using special knives in size of 4-5 micrometer.

Staining

The most common staining technique, Hematoxylin and Eosin (or H&E) staining were used.

Permanent Mounting

After staining the sections were again dehydrated with ascending alcohols (95 % and 100 %) and xylene, prior to covering with a mountant and a glass coverslip. Mountants need to have good optical properties. The slides were left for at least 24 hours for the mountant to dry. The finished (permanent) slide dried at 50 °C in oven for few hours and allowed mounted slide to dry lying flat for at least 1 week.^[12]

Dead Space Wound Model

Wistar rats of either sex weighing 150-200 g were procured and maintained at standard housing conditions. The animals were randomly divided into four groups of five rats each. Under ketamine-xylazine (ketamine 60 mg/kg and xylazine 5 mg/kg i.p.) anaesthesia, dead space wounds were created by subcutaneous implantation of sterilized cotton piths of 10 mg on the right side groin and axilla on the ventral surface of each rat. All the groups were treated as per the treatment schedule. The granulation tissues formed on the cotton piths were excised carefully on the 10th post wounding day under light ether anesthesia. The tissue is dried overnight 50°C-60°C and the dry

granulation tissue weight was recorded on 11th day.^[13,14]

Sample preparation

Small tissue samples were hydrolyzed without preliminary purification by adding 5 ml of 6N hydrochloric acid. The sample were sealed in test tube and hydrolyzed for 3 h at 130 °C. The tubes were then opened and the contents were decanted into a graduate cylinder or volumetric flask. The tubes were washed thoroughly with water, and the washings were combined with the hydrolyzate. Several drops of 0.02 % Methyl red indicator and 2.5 N sodium hydroxide required for neutralization was added. Final adjustment was made with dilute hydrochloric acid and Sodium hydroxide until the indicator turn slightly yellow corresponding to pH 6-7.

Method for determination of Hydroxyproline

The samples were prepared as above and 2 ml portion containing 1-5 µg hydroxyproline was placed in test tubes. A series of standard was prepared containing 0-5 µg hydroxyproline in 2 ml total volume. Hydroxyproline oxidation was initiated by adding 1 ml chloramine T to each tube. The tube content was mixed by shaking a few times and allowed to stand 20 minutes at room temperature. The chloramines T was then destroyed by adding 1 ml perchloric acid to each tube in the same order as before. The content were mixed and allowed to stand for 5 minutes. Finally 1ml p-dimethylaminobenzaldehyde solution was added and the mixture was shaken. The tubes were placed at 60 °C over water bath for 20 minutes then cooled in a tap water for 5 minutes the developed color was stable for at least 1h and the absorbance of the solutions were determined spectrophotometrically at 557 nm. The hydroxyproline value was determined directly from linearity data of the standard curve.

Result and Discussion

Incision Wound

The tensile strength of incision wound model was found to be significant, *MTEE* 5 % (512.9 ± 12.04) and *MTEE* 10 % (546.8 ± 7.27) when compared with control (399.5 ± 11.0) and povidone iodine (5 % w/w) also showed significant effect (608.7 ± 9.8). The incision wound model of *MTEE* 10% on day 0 and complete healing on the day 9 are presented in figure (a, b, c and d below) and the tensile strength of incision wound models are presented in table no.1.

Dead space wound

In dead space wound model, the treated groups *MTEE* 5 % and *MTEE* 10 % topical, showed significantly increased weight of granuloma by 55.33 mg and 67.19 mg respectively when compared with control 30.89

mg. Povidone iodine (5 % w/w) also showed significantly increased weight of granuloma by 72.10 mg. The treated groups *MTEE* 5 % and *MTEE* 10 % topical showed significant increase in the hydroxyproline content by 2.93 µg/ml and 4.31 µg/ml respectively when compared with control 1.52 µg/ml. Povidone iodine (5 % w/w) also showed significantly increase in hydroxyproline content by 5.12 µg/ml. The weight of granuloma and hydroxyproline content are presented in table no.1

Histopathological study

The multiple sections studied in histopathological examination of the tissues of the healed incision wound treated with the ethanolic extract 5% w/v and 10% w/v, povidone-iodine ointment 5% w/w, and normal saline (control) treated groups are shown in Figure- a), b), c) and d) The histological examination showed that the original tissue regeneration was much greater in the skin wound treated with extracts (Figure- b and c) and povidone-iodine ointment treated group (Figure-d) without any oedema, congestion or inflammatory changes. The histological studies of the granulation tissue of the control group of animals (Figure-a) showed more aggregation of macrophages with lesser collagen fibers. More relative fibrosis was observed in the povidone-iodine and 10% w/v treated wound with comparing to the skin wound treated with 5% w/v and control.

The result of present study showed that *Malvastrum tricuspidatum* possesses a definite pro-healing action.

In incision wound model ethanolic extracts 10 % w/v topical showed significant increase in tensile strength of incision wound on 10th post wounding day against control. This increase in tensile strength of treated wounds may be due to increase in collagen concentration and stabilization of the fibres. The histological examination showed that the original tissue regeneration was much greater in the skin wound treated with extracts (Figure- b and c) and povidone-iodine ointment treated group (Figure-d) without any oedema, congestion or inflammatory changes. The histological studies of the granulation tissue of the control group of animals (Figure-a) showed more aggregation of macrophages with lesser collagen fibers. More relative fibrosis was observed in the povidone-iodine and 10% w/v treated wound with comparing to the skin wound treated with 5% w/v and control.

In dead space wound model ethanolic extracts 10 % w/v topical significantly increases of weight of granuloma and hydroxyproline content against control. The increased amount of hydroxyproline content in treated group underlines increased collagen content

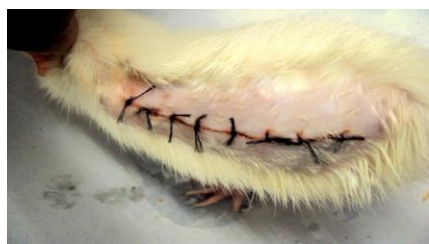since hydroxyproline is the direct estimate of collagen synthesis which supports the wound healing activity of *Malvastrum tricuspidatum*. Post-operative wounds are commonly known to be infected, earlier studies have shown that antibacterial activity of the plant supports wound healing. Further the plant has been evaluated for antibacterial activity by previous researchers. Hence, present research supports traditional claims of plant in wound healing. *Malvastrum tricuspidatum* ethanolic extract 10% w/v in normal saline topically showed better activity than all other treated groups. Ethanolic extracts 10% topical significantly increases in tensile strength of incision wound on 10th post wounding day by 546.8 g against control 399.5 g in incision wound model. Ethanolic extracts 10% topical significantly increases weight of granuloma by 67.19 mg against control 30.89 mg and L-hydroxyproline content by 4.31 µg/ml against control 1.52 µg/ml in dead space wound model.

The histological examination showed that the original tissue regeneration was much greater in the skin wound treated with extracts and povidone-iodine ointment treated group when compared with control.

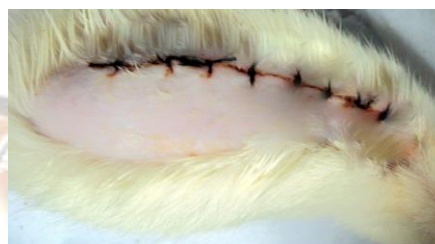In the present study we found that ethanolic leaf extract (10% w/v topical) promoted the wound healing activity significantly in all the wound models. High rate of wound contraction, decrease in period for epithelialisation, high skin breaking strength and granulation strength, increase in dry granulation tissue weight, elevated hydroxyproline content and increased collagenation in histopathological section were observed in animals treated with ethanolic leaf extract when compared to control. The findings suggest that *Malvastrum tricuspidatum* can be used as prophylaxis or as adjunct with other therapy for better wound healing effect.

References

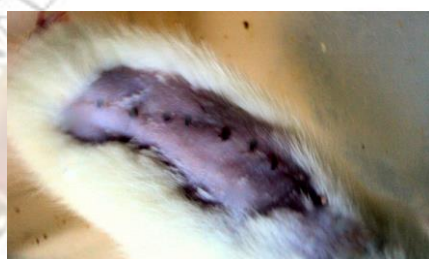1. Alam MS, Chopra N, Ali M, Niwa M. A new lactone from *Malvastrum Coromandelinum*. *Indian J Chem*, 1996; 35B (12):1354-1355.
2. Kallapa MH, Raviraj SP, Dheeraj VC. A moderate source of cyclopropenoid fatty acids in *Malvastrum tricuspidatum*. *Medicinal Aromatic Plant Sci Biotech*, 2004; 26(2).
3. Khonsung P, Nantsupawat S, Jesadanont SN, Chantharateptawan V, Panthang A. Anti-inflammatory and Analgesic Activities of water extract of *Malvastrum coromandelianum* (L.) Garcke. *Thai J Pharmacol*, 2006; 28(3):9-15.
4. Sittiwet C, Jesadanont S, Pongpech P, Naenna P, Pongsamart S. Antibacterial activity of *Malvastrum coromandelianum* Garcke against methicillin-sensitive and methicillin-resistant strains of *Staphylococcus aureus*. *Current Res Bacteriol*, 2008; 1(1):42-45.
5. Ibrar M, Hashim S, and Marwat K B. Ethnobotanic study of the weeds of five crops in district Abbottabad, N-W Pakistan. *Pak J Weed Science Research*, 2003; 9(3-4):229-240.
6. Srivastava S.N, Kapoor LD, Singh A, Kapoor SL, Survey of Indian plants for saponins, alkaloids and flavonoids I. *Lloydia*, 1969; 32:297-304.
7. Mukherjee PK, Verpoorte R, Suresh B. Evaluation of In-vivo wound healing activity of *Hypericum patulum* (Family: Hypericaceae) leaf extract on different wound model in rats. *J Ethnopharmacol*, 2000; 703:15-21.
8. CPCSEA- Committee for the Purpose of Control and Supervision on Experiments on Animal, protocols and standard guidelines.
9. Ehrlich HP, Hunt TK. Effect of cortisone and anabolic steroids on the tensile strength of healing of wound. *Ann Surg*, 1969; 170: 203-206.
10. Lee KH 1968. Studies on the mechanism of action of salicylates. Effect of vitamin A on wound healing retardation of aspirin. *J Pharmacol Sci*, 57: 1238-40.
11. Pritam S. Jain, Sanjay B. Bari. Evaluation of wound healing effect of petroleum ether and methanolic extract of *Abelmoschus manihot* (L.) Medik., Malvaceae, and *Wrightia tinctoria* R. Br. Apocynaceae, in rats. *Brazilian Journal of Pharmacognosy*, 2009:756-761.
12. Md.Sadequel Islam Talukder. MACP (USA). Department of pathology, Histopathology Techniques, Page 1-11. www.Talukderbd.com
13. Nayak BS, Pereira LP, Maharaj D. wound healing activity of *Carica papaya* L. in experimentally induced diabetic rats. *Indian J Exp Bio.*, 2007; 45:739-743.
14. Patil SM, Patil MB, Somapur CK. Evaluation of wound healing properties of *Saussurea lappa* Clarke root extracts. *Adv Pharmacol Toxicol.*, 2009; 10(2):85-90.



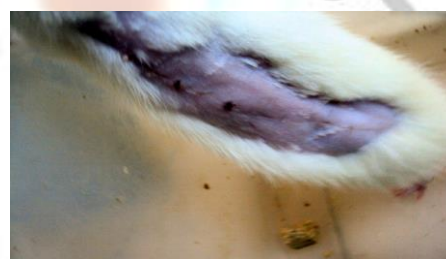(a) MTEE 10% Day-0



(b) MTEE 10% Day-4



(c) MTEE 10% Day-7



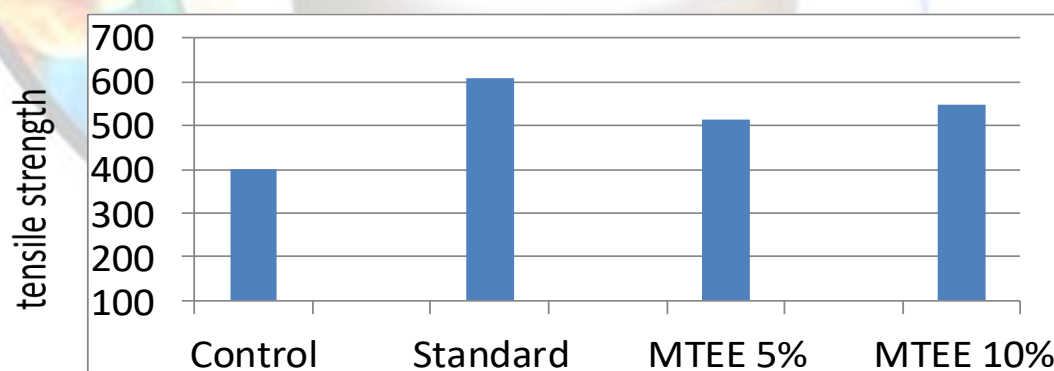
(d) MTEE 10% Day-9

Table 1: Effect of ethanolic extract of *Malvastrum tricuspidatum* on incision wound and dead space wound

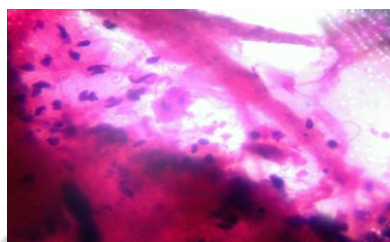
Group	Treatments (Topically)	Incision wound	Dead space wound	
		Tensile strength on 10 th day (g)	Granuloma wt. (mg/100g)	Hydroxyproline content (µg/ml)
I	Control (saline)	399.5 ± 11.0	30.89±0.85	01.52±0.083
II	MTEE-T (5% w/v in saline)	512.9 ± 12.04 ^{bd}	55.33 ± 1.07 ^{bc}	2.93 ± 0.24 ^{bd}
III	MTEE-T (10% w/v in saline)	546.8 ± 7.27 ^{bd}	67.19 ± 1.36 ^b	4.31 ± 0.19 ^{bc}
IV	Standard (Povidone-Iodine)	608.7 ± 9.8 ^b	72.10±3.37 ^b	5.12±0.21 ^b

T= Topical application, All data was subjected to ANOVA followed by Tukey Kramer test and the values are reported as mean ± SEM (n=5)

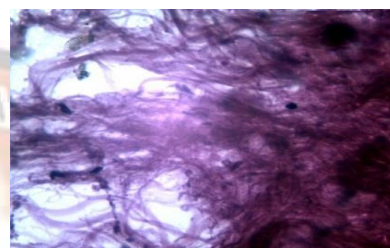
^ap<0.05, ^bp<0.01 when compared to control and ^cp<0.05, ^dp<0.01
Where, MTEE-T: *Malvastrum tricuspidatum* ethanolic extract-topical



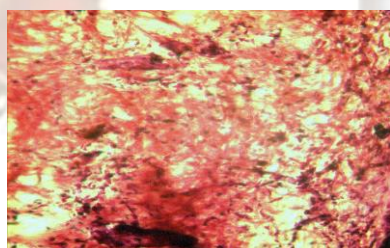
Effect of MTEE 5% and MTEE 10 % when compared with standard povidone iodine and control



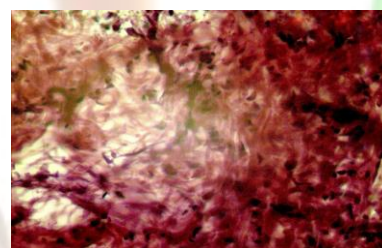
(a) Normal Saline (control)



(b) 5% w/v ethanolic extract
of *Malvastrum tricuspidatum*



(c) 10% w/v ethanolic extract
of *Malvastrum tricuspidatum*



(d) 5% standard (P.I)

Table 2: Summary of different models on different doses

Plant	Dose*	Incision wound model	Dead space wound model
Povidone Iodine (standard)	5%	↑ +++	↑ +++
<i>Malvastrum tricuspidatum</i> (Treated)	5%	↑ ++	↑ +++
	10 %	↑ +++	↑ +++

*Dose in % w/v of ethanolic extract of *Malvastrum tricuspidatum* topically.

+ - indicates mild activity
 ↑
 ++ - indicates average activity
 ↑
 +++ - indicates strong activity
 ↑