



Cardioprotective effect of grapeseed proanthocyanidin on doxorubicin induced myocardial injury in rats

M. Abirami and U. Kanagavalli*

Department of Biochemistry,
Adhiparasakthi College of Arts & Science, G. B. Nagar, Kalavai, Vellore, (TN) - India

Abstract

Grapeseed Proanthocyanidin [GSP] seeds possessing a potent antioxidant and cardioprotective properties were evaluated against Doxorubicin induced cardiotoxicity in rats. Intraperitoneal injection of DOX [10mg kg^{-1} /b.wt] administrated once a day for 15 days was revealed by elevated serum creatine phosphokinase [CPK] lactate dehydrogenase [LDH] aspartate transaminase [ASP] alanine transaminase [ALT] HDL cholesterol and triglycerides in comparison of control and associated with increasing levels of myocardial malondialdehyde [MDA] with simultaneously decrease in the level of glutathione peroxidase [Gpx], glutathione-S transferase [GST] and glutathione reductase [GR] daily oral administration of aqueous suspension of GSP seeds extract in the dose of (200 mg/kg/b.wt) for 15 days produced normalization in the serum levels of heart marker enzymes. So the study shows that GSP seeds possess antioxidant and cardioprotective effect.

Key-Words: Grape seed proanthocyanidin, Doxorubicin, Myocardial Injury, Antioxidant

Introduction

Doxorubicin [DOX, Adriamycin] is a member of the Anthracyclin drug family and one of the most frequently used drug to treat many forms of cancer such as leukemia, lymphoma and solid tumors [1]. Doxorubicin is one of the important antitumor agents having a variety of an therapeutic potency against variety of human tumors including soft tissue sarcoma, breast cancer, small cell carcinoma of the lung and acute leukemias. Cardiac cells are the most sensitive to the effects of Doxorubicin followed by the sarcoma and melanoma cells normal muscle fibroblast and normal skin fibroblast. Doxorubicin also has immuno suppressive activity [2]. Dox induced myocardial damage [3-5]. Free radicals may be formed by infiltration of white cells in to ischemic myocardium or may be formed in the endothelial cell by the action of xanthine oxidase during period of ischemia [6]. The pathophysiological changes following Dox administration are compare to those taking place in human myocardial alteration [7].

Ischemic heart disease is the another disease of the heart by itself characterised by reduced blood supply to the organs [8]. A better understanding of the process involved in myocardial injury has stimulated the search for new drugs.

Medicinal plants that have been found to have certain preventive measures in the treatment of [IHD] ischemic heart disease. Grape seed proanthocyanidins [GSP] have gained considerable attention due to their wide range of biological and pharmacological properties [9-10].

Material and Methods

Drugs and chemicals

Doxorubicin [Adrim] was purchased from Apollo Pharma Limited, Chennai, India. All other chemicals and solvents used were of the highest purity and analytical grade.

Collection of plant material

The seeds of Grape seed Proanthocyanidins were collected manually during month of Feb 2011.

Extraction of plant material

The plant seed were freed of pericarp, shade dried and powdered in a mixer and the extract was prepared described earlier. The seeds were manually separated. 100gm of the seed powder was extracted with 70% ethanol at 50 to 60°C in a soxhlet apparatus for 72hrs. The liquid was cooled and concentrated by its liquid content in vacuum and freeze dried. An approximate yield of 15% was obtained. The extract of Grape seed Proanthocyanidin seed will be called as GSP.

Animals

Animals healthy Wister adult male rat between 100-180g were used for this purpose. The animals were

* Corresponding Author

E.mail: kanagakumareash07@gmail.com

housed in polypropylene cages and maintained at 24±2° under 12hrs light dark cycle and were fed with standard pellet diet and had free access to water maintenance and use of animals as per the experiments was approved by the institutional animal Ethics committee APCAS/IAEC/2011/11

Experimental protocol

The rats were divided into six groups of six rats each as follows:

GROUP I: Control rats received distilled water [1ml/kg body weight] orally for 15 days.

GROUP II: Simultaneously IV administration of 5 micro mole/kg of verapamil [IV] and DOX 10mg/kg [IV] were given and sacrificed after 48hrs.

GROUP III: Rats were injected intra peritoneal with a single dose of DOX [10mg/kg IV] in normal saline and animals were sacrificed after 48hrs.

GROUP IV: Rats were administered DOX as in group II and pretreatment with GSP extract [200mg/kg body weight] before one hour DOX treatment by oral gavage for 15 consecutive days. The blood samples were collected.

After the 15 days experimental period (i.e., on the 16th day), all the animals were anesthetized and were sacrificed and isolated heart. The heart tissue homogenates were prepared in 0.1M Tris HCL buffer PH 7.4 were used for the determination of lipid peroxides [Lpo] reduced glutathione [GSH] glutathione peroxidase [Gpx] glutathione s-transferase [GST]. The serum was used for the determination of aspartate amino transferase [AST] alanine amino transferase [ALT] lactate dehydrogenase [LDH] creatinine phosphokinase [CPK] glucose, total cholesterol, lipid profiles [LDL, HDL, VLDL] and triglycerides.

Statistical analysis

The statistical analysis was carried out using analysis one-way analysis of variance (ANOVA) followed by Dunnett's test using Graph pad. P values <0.05 were considered as statistically significant condition.

Results and Discussion

Many plants derived drugs used in modern medicine are developed by ethno Medical leads and subsequent ethno pharmacological study. Plant containing flavanoids have been reported to possess a strong antioxidant properties [11]. Grape seed contain polyphenol of members of the proanthocyanidins structurally, the proanthocyanidin are a group of complex compounds made up of oligomers and polymers of poly hydroxy flavan-3-ol monomer units [12].

Several epidemiological studies have suggested that the mortality rate from coronary heart disease can be decreased by moderate consumption of alcohol, particularly red wine [13], proanthocyanidins found in seeds of the grapes and relatively abundant in red wine, have been thought to be the major components responsible for such epidemiological observations [14]. In the present study we explored the possible use of proanthocyanidin from grape seed as a therapeutic drug in myocardial protection against DOX induced myocardial injury.

Table 1 shows the level of diagnostic marker enzyme [AST, ALT, LDH, and CPK] in serum significantly increased in group III animal [DOX induced] when compared to control [group I].

The ethanolic extract of grape seed [group IV] at the dose of 200mg/kg body weight significantly [p<0.05] decreased in the enzyme level in serum when compared to DOX treated animal [group III].

Grape seed [group IV] at a dose of 200mg/kg body weight produced a non-significantly decreased in the enzyme activity of [AST, ALT, LDH, CPK] and non-significantly increased activity of LDH when compared to control animal].

Several studies revealed that generation of free radical decreased the antioxidant defense mechanism thereby by damage cellular constituent, glutathione (GSH), extensively found in cells, against electrophilic attacks provided by drugs such as free radicals and peroxides. GSH deficiency leads to cellular damage in kidney, liver and heart, the elevation of MDA levels, which is one of the end products of lipid peroxidation in the heart muscle tissue, and the reduction of cardiac GSH levels are important indicators in DOX-intoxicated rats. DOX is capable of generating super oxide free radicals, thereby suppressed the GSH synthesis and increasing MDA levels due to peroxidation of polyunsaturated fatty acid of myocardial membranes [15]. DOX produces acute injury to the myocardial membrane which causes significant elevation of marker enzyme [AST, ALT, LDH, CPK] activities in serum could be regarded as a sign of damage to the heart muscle membrane, which suggest the event of enhanced lipid peroxidation. Several literature revealed that the elevation of lipid peroxidation lead to depletion of GSH in DOX induced rats. Leading to tissue damage and failure of antioxidant defense mechanism to prevent the formation of excessive free radicals [16-17]. In present study grape seed proanthocyanidin extract prevent the leakage of marker enzymes by scavenging lipid peroxides and improve the GSH levels thereby by protecting integrity of membrane. The antioxidant enzymes, constituting the first line of defense

mechanism to prevent and neutralize the reactive oxygen species (ROS) induced damage. This accomplished by a set of endogenous antioxidant enzymes such as (GR and GST), whose activities are dependant on the level of reduced glutathione(GSH),it as been well documented that depletion of GSH and elevation of lipid peroxide leads to decrease in antioxiide enzyme DOX induced rats^[18].

Lipid consist of cholesterol (HDL and LDL cholesterol), triglyceride (neutral fat), In the present studies shows that DOX reduced the rate of lipolysis whereas markedly elevation of TG, HDL, LDL, levels in DOX induced cardiomyopathy, which is agreement with previous studies[18].Supplement of grape seed proanthocyanidin extract brought back near to normal lipid profile. It has been reported for its ability to scavenge the reactive oxygen species such as OH and superoxides also inhibits the lipidperoxydation^[19-20] So we concluded that oral administration of grape seed proanthocyanidin seed have been shown to modulate the biochemical changes observed in DOX induced cardiotoxicity in animals. Flavanoids have been shown to inhibit lipid peroxidation formation in rat tissues and also inhibit the free radical production in the cells at various stages. In this context, we have reported that GSP treatment reduced the levels of heart TBARS in DOX induced lipid peroxidation.^[21]

Lipids play an important role in cardiovascular disease, not only by way of hyperlipidaemia and the development of atherosclerosis, but also by modifying the composition, structure and stability of cellular membranes. Excess lipids in blood is considered to accelerate the development of arterosclerosis and are the major risk factor in myocardial infarction. High levels of circulating cholesterol and its circulation in heart tissue are well associated with cardiovascular damage^[22]. An altered lipid metabolism can alter the cardiac function by changing the properties of cardiac membrane and these changes may contribute to the cell death that follows coronary artery occlusion^[23]. The cardiac muscle generally utilizes fatty acid as the major source of energy of the total oxygen consumption: 60-90% is utilized to oxidize fatty acid under aerobic condition. Under anoxic conditions, the cardiac muscle is not in a position to oxidize the available fatty acids, as a result of which there is an increase in the levels of these long chain fatty acyl coA derivatives^[24].

DOX treated rats showed increased levels of total, free and ester cholesterol, triglycerides and acids in serum of rats. An increase in serum LDL and VLDL fraction, along with a decrease in HDL cholesterol, were also observed in DOX treated rats. These changes could be

due to enhanced lipid biosynthesis by cardiac cyclic adenosine mono phosphate

^[25]. High levels of LDL in fractions, whereas high levels of HDL cholesterol have a negative correlation^[26-29].

Histoarchitectural Studies

The parts of the hearts stored in 10-percent (w/v) buffered formalin were embedded in paraffin,sections cut at 5 µm, and stained with hematoxylin and eosin. These sections were examined under a lightmicroscope for histoarchitectural changes

Conclusion

The present study provides experimental evidence that grape seed Proanthocyanidin (GSP) decides its various pharmacological activities also has strong anti oxidant properties. This finding might be rational to understand the beneficial effects of GSP in cardio protection against DOX induced myocardial injury.

References

1. Singal P.K Lillskvic N.S., Hill M.S Thomson T.p and L.T [1995] combination therapy with probaccol prevents adriamycin-induced cardiomyopathy.J.Mol cell cardiol. 27:1055-1063.
2. Text book of pharmacology by Rang Dare Riteer 4th edition.
3. Tappel A. lipidperoxidation and damage to cell components fed proc 1973;32:1870-4,
4. Singal Pk, Dhalla A.K.Hill M.Thomas TP. Endogenous antioxidant changes in the myocardium in response to acute and chronic stress conditions. Mol cell biochem 1993;129:176-186.
5. Maulik N.Engermen D.T watanable m.etal nitricoxide signaling in ischemic heart. Cardiovaspes 1995;30:593-601.
6. MC cord JM, Roy RS. The pathophysiology of superoxide roles in inflammation and ischemic can J physiol pharm 1982 60.1346-1352. The pathophysiology changes following DOX administration are compare to those taking place in human myocardial alterations.
7. Waxler BC myocardial infraction in young versus old male rats pathophysiology changes an heart 1978:70-80.
8. "Eating for a healthy heart" medicine web.http//www.medicine web.com/nutrition -/eating for-a healthy heartretrive 2009-2003-31.
9. Bors W. Fool LY. Hertkorn N.michel C.stetimaies k.chemical studies of proanthocyanidins and hydroobletams antioxidant redox signal 2001; 3.995-1008.
10. Bagchi D. Bagchi M. Stohs SS. Ray SD, Sen CK prvess Hg leular protection with

- proanthocyanidins derived from GSP arm HG Acad pathol 1959; 1967 43-58.
11. Raj KJ, Shalini K. flavonoids- a review of biological activities. Indian drugs 1996; 36; 668-76.
 12. Rice-Evans CA, Miller NJ, Paganga G. Structure—antioxidant activity relationships of flavanoids and phenolic acid. Free Radical Biol Met 1996; 20:933-56.
 13. Renaud S, De Lorgeril M. Wine, alcohol, platelets, and the French paradox for coronary heart disease. Lancet 1992; 339:1523-6.
 14. Constant J. Alcohol, ischemic heart disease, and the French paradox. Coron Artery Dis 1997; 8:645-9.
 15. Daosukho C., Chen Y., Noel T., Sompol P., Nithipongvanitch R., Velez J.M., Oberly T.D. and St. Clair D.K. (2007). Phenylbutyrate, a histone deacetylase inhibitor, protects against adriamycin-induced cardiac injury. Free radic. Biol Med., 42:1818-1825.
 16. Deepa P.R. and varalakshmi P. (2003). protective effect of low molecular weight heparin on oxidative injury and cellular abnormalities in adriamycin-induced cardiac and hepatic toxicity. Chem. Biol. Interact., 146 : 201-210.
 17. Gnanapragasam A., Ebenzer K.K., Sathish V., Govindaraju Pand, Devaki T. (2004). Protective effect of centella asiatica on antioxidant tissue defense system against adriamycin induced cardiomyopathy in rats. Lif Sci., 76:585-597.
 18. Rajaprabhu D., Rajesh R., Jeyakumar R., Buddhan I S., Ganesan I B. and Anandan R. (2007). Protective effect Picrohiza kurroa on antioxidant defense status in adriamycin induced cardiomyopathy in rats. Journal of Medicinal Plant Research, 1(4):80-85.
 19. Ursini, F., Maiorino M. and Brigelius-Flohe R. Et al (1995). The diversity of glutathione peroxide meth enzymol. 252:38-63.
 20. Kasiappan R., Balasubramanian R and Sorimuthu S. (2004). Effect of Eugenia jambolona seed kernel on antioxidant defense system in streptozotocin – induced diabetes in rats. life science, 75(22):2717-2731.
 21. Hoda E. Mohameda, Sahar E. EL-Swefy and Hanan H. (2002). The protective effect of glutathione administration on adriamycin induced acute cardiotoxicity in rats. Pharmacological Research, 42,(2):115-120.
 22. Korina L.G. and Afana I.B. (1997). Antioxidant and chelating properties of flavonoids. Adv. Pharmacol., 38:151-163.
 23. Abalea V., Cillard J., Dubos M.P., Sergeant, O., Cillard P. and Morel I. (1999). Repair of iron-induced DNA oxidation by the flavinoid myricetin in primary rat hepatocyte culture. Free Radiac. Biol. Medi., 26:1457-1466.
 24. Bajpai M., Pande Anurag T., and prakash S. K. (2005). Phenolic contents and antioxidant activity of some food and medicinal plants. international journal of Food sciences and nutrition, 56,(4):287-291.
 25. Karthikeyan, K., saralabai, B.R., Niranjali Devaraj, S. (2007). Cardioprotective effect of grape seed proanthocyanidins on isoproterenol-induced myocardial injury in rats. Int. J. Cardiol. 115, 326-333.
 26. Salter, A.M., White, D.A., (1996). Effects of dietary fat on cholesterol metabolism: regulation of plasma LDL concentrations. Nutr. Res 9, 241-257
 27. Katz, A.M., Messineo, F.C. (1981). Lipid-membrane interactions and the pathogenesis of ischemic damage in the myocardium. Circ. Res. 48(1), 1-16
 28. Whitmer, J.T., Idell-wenger, J.A., Rovetto, M.J., Neely, J.R. (1978). Control of fatty acid metabolism in ischemic and hypoxic hearts. J. Biol. Chem. 253 (12), 4305-4309.
 29. Paritha, I.A., Devi, C.S., 1997. Effect of α -tocopherol on isoproterenol-induced changes in lipid and lipoprotein profile in rats. Indian J. pharmacol. 29, 399-404.
 30. C.B., Breslow, J.L., Hennekens, C.H., (1992). Decreased HDL-2 and HDL-3 cholesterol, Apo A-I and Apo A-II and increased risk of myocardial infarction. Circulation 85, 22-29.

Table 1: Effect of Doxorubicin and GSP on the activities of cardiac marker enzyme in serum

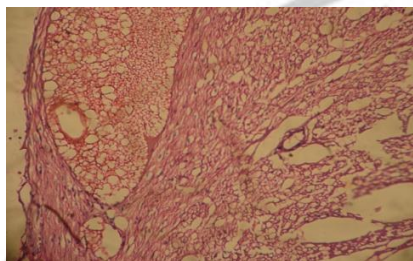
S/ No.	PARAMETER	CONTROL	STANDARD	INDUCER[DOX]	TREATMENT
1.	AST	191.67±4.88	185±0.5	201.67±4.71	182.6±4.20
2.	ALT	28.04±2.06	20.12±1.084	76.39±7.03	20.5±1.83
3.	LDH	660.67±6.43	596±31.2	292±6.63	610.5±4.83
4.	CPK	52.12±7.035	58±3.401	185±4.070	56±8.035

Table 2: Effect of grape seed Proanthocyanidin on Gpx, GST, GR, in rat serum

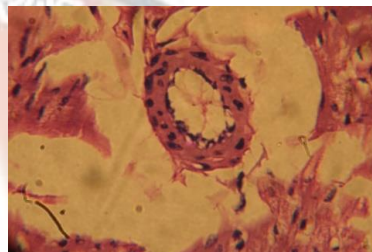
GROUP	CONTROL	STANDARD	INDUCER[DOX]	TREATMENT
GPx (nmoles GSH oxidized min ⁻¹ mg ⁻¹ proten)	4.69±0.08	4.62±0.05	1.26±0.13	3.51±0.04
GST(nmoles CDNB conjugate formed min ⁻¹ mg ⁻¹ protein)	189.42±0.44	186.4±1.35	0.40±0.036	184.39±0.33
GR(nmoles NADPH oxidized min ⁻¹ mg ⁻¹ protein)	1.25±0.12	2.26±0.10	0.79±0.55	1.18±0.06

Table 3: Effect of Doxorubicin and GSP on the Lipid profile in serum

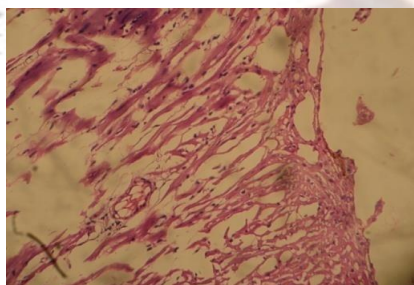
S/NO	PARAMETER	CONTROL	STANDARD	INDUCER[DOX]	TREATMENT
1.	TOTAL CHOLESTROL	94.71±8.95	135±2.01	139.36±9.97	90.15±8.31
2.	TG	105±2.073	89.9±3.45	105±2.073	96.2±1.075
3.	HDL	34.54±4.11	36.1±2.48	16.63±1.50	22.64±3.15
4.	LDL	78.41±5.22	65.6±1.96	98.60±10.62	61.31±9.11
5.	VLDL	6.54±0.84	3.53±3.20	15.14±1.26	9.64±1.87



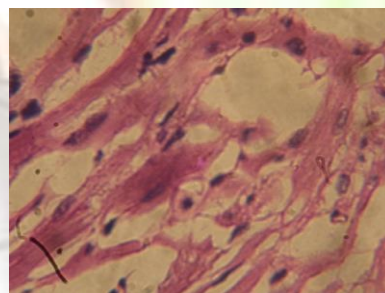
Control rats showing normal morphological appearance



DOX - treated rat showing focal fibrillar loss and cytoplasmic vacuolization



DOX – treated verapamil showing less focal fibrillar loss and cytoplasmic vacuolization



DOX – treated GSP (200 mg/kg) showing less focal fibrillar loss And sytoplasmic vacuolization