



## INTERNATIONAL JOURNAL OF PHARMACY & LIFE SCIENCES (Int. J. of Pharm. Life Sci.)

### Histopathological Changes in liver tissue induced by meloxicam in male mice

Najat M. H. Mohammed<sup>1\*</sup>, Ezzat El-Drieny<sup>1</sup>, Ibrahim S. El-Drussi<sup>2</sup>, Masouda Al-agory<sup>1</sup> and  
Ebtesam M. M. Gheth<sup>2</sup>

1, Histology Department, Faculty of Medicine, Omar Al-Mukhtar University, El-Beida, Libya

2, Zoology Department, Faculty of Science, Omar Al-Mukhtar University, El-Beida, Libya

#### Abstract

Despite of the frequent utility of non-steroidal anti-inflammatory drugs (NSAIDs) in the treatment of osteoarthritis related diseases, as they have analgesic antipyretic and anti-inflammatory effects, they have been currently proven to cause deleterious toxic effects to the hepatic tissue. Meloxicam is a new version of NSAIDs classified as selective cyclooxygenase-2 inhibitor (COX-2) which may have a protective role over the old traditional types (non-selective COX-1 inhibitor), therefore, the aim of the study was to investigate whether meloxicam could have toxic pathological effects on the liver tissue like other traditional drugs. Fifteen adult male mice were divided into two groups, one group of five mice served as control and received only distilled water, while the animals of the second group (10 mice) was treated with meloxicam 0.4 mg/kg administrated daily by oral gastric gavage for 10 days. After 24 hours of the last dose, animals were sacrificed, their livers were removed and processed for histological examination by light microscope. The liver sections obtained from meloxicam treated mice showed dilatation and congestion of blood sinusoids, as well as portal venous congestion. Appearance of degenerative changes of hepatocytes was found in forms of cytoplasmic vacuolations and nuclear pyknosis as well as glycogen depletion. In addition, mononuclear cellular infiltration, areas of hemorrhage and necrosis were evident. Focal loss of normal hepatic architecture was also observed. It could be conclude from this study that meloxicam might cause mild to moderate hepatotoxicity.

**Key- words:** Meloxicam, liver, mice, NSAIDs

#### Introduction

Non-steroidal anti-inflammatory drugs (NSAIDs) are most commonly used as therapeutic drugs. They are effective in treatment of some disorders such as rheumatoid arthritis, inflammatory joint diseases, cancer and Alzheimer's, as they have analgesic, anti-inflammatory and antipyretic properties<sup>[1,2,3]</sup>. However, frequently use of such type of drugs is associated with a higher incidence of hepatotoxicity and nephrotoxicity<sup>[4]</sup>.

In the previous years, the majority of NSAIDs that are available belong to traditional non-selective (ns-NSAIDs) group which show their therapeutic effect by decreasing prostaglandin synthesis through inhibition of cyclooxygenase enzymes (COX)<sup>[1,5]</sup>. Two isoforms of COX1 and COX2 enzyme have been recognized<sup>[1,5]</sup>.

COX-1 enzyme in all body tissues and is responsible for generating prostaglandin that are normally important for maintaining organ function, intestinal integrity and blood hemostasis<sup>[2,6]</sup>. While COX-2 enzyme which is expressed on kidney and vessels endothelium is responsible for generating prostaglandins (PE2) induced by pathological condition<sup>[6,7]</sup>.

Non-selective NSAIDs act by inhibiting both COX1 and COX2. However, the desired effects that are needed is to inhibit only COX2 over than COX1<sup>[2]</sup>. Diclofenac (particularly sulindac) is reported to cause severe hepatocellular damage about 5-10 folds than other NSAIDs<sup>[8,9,10]</sup>. Therefore, such of these drugs were withdrawn form clinical use.

Meloxicam is one of the popular drugs with selective COX2 inhibitory effect and is designed to leave protective effect of COX1 products which might be useful than ns-NSAIDs<sup>[4]</sup>.

Recent animal studies have been reported that using of selective COX-2 inhibitor drugs (Brand name

\* Corresponding Author

Celecoxib) are also associated with hepatotoxicity<sup>[8,11]</sup>. Although, they have less potential degree of toxicity as compared with other research findings with non-selective type (ibuprofen)<sup>[8,11]</sup>.

The aim of this study was to investigate liver histologic changes in mice induced by meloxicam.

### Material and Methods

The study was conducted in Histology Department, Faculty of Medicine, Omar Al-Mukhtar University. Fifteen male mice were used and their average weight 23g. These animals were obtained from experimental animal house of Veterinary Faculty. All animals were maintained under standard condition in the laboratory at least one week before use with standard food and tap water were provided ad libitum throughout experiment. They were divided into two group: the first is the control group (5 animals) housed in one cage. While the other group is treatment one (10 animals) treated with meloxicam.

**Treated group:** Animals received 0.4mg/Kg of meloxicam which equalizes to human therapeutic dose (15mg/Kg)<sup>[4]</sup>. Each tablet of meloxicam (Mobic, Boehringer, Ingelheim, Germany) was dissolved in 75ml of distilled water and each animal was given 0.05ml of freshly prepared solution once daily in the morning after food supplement by gastric gavage for 10 days.

**Control group:** Animals dosed with distilled water with same volume used in experimental animals

At the end of experiment, animals were anesthetized by chloroform and sacrificed and livers removed from each animal, then fixed by 10% buffered formalin and processed by routine histopathological technique. The prepared slides were stained by Hematoxyline and Eosin (H&E) and Periodic acid Schiff's (PAS) stain.

### Results and Discussion

#### Control group

Light microscopic examination of liver sections obtained from the control group stained with H&E showed normal histological structure of liver in the form of central vein, surrounding hepatocytes and normal sinusoidal lumens (Fig 1 A).

In addition, examination of liver sections stained with PAS showed normal amount of glycogen contents inside hepatocytes (Fig 4 A). Some of control sections were treated with diastase in order to use as negative control (Fig 4 B).

#### Experimental group

There were some histological changes observed in livers of treated animals with meloxicam. Sinusoidal dilatation and congestion (Fig 1 B& Fig 2 A), and congestion of portal veins were also observed (Fig 2

A). Focal hemorrhage, hepatocellular necrosis (Fig 2 A & Fig 3 G, H) and mild mononuclear cell infiltrations were also seen (Fig 3 H). In addition, hepatocytes of Zone I & II (periportal region) showed degenerative changes, while in the area near central veins (Zone III) appeared quite normal (Fig 2 B). Hepatocellular degeneration was involving abundance of cytoplasmic vacuoles and nuclear pyknosis (Fig 2 B&C). Focal areas appeared with complete loss of hepatic architecture (Fig 2 C).

Histochemical staining with PAS, hepatocytes showed mild to moderated depletion of glycogen contents particularly those around portal area (Fig 4 C&D).

NSAIDs are the most popular analgesics used in large number in rheumatological related disorders. Traditional non selective COX 1 inhibitors have been implicated with serious adverse events. Shifting to a new version of NSAIDs (selective COX 2 inhibitor) drug is believed to be more protective and safer than using traditional COX1 inhibitor<sup>[1,2]</sup>. However, it has been noted recently that those types of drugs may induce hepatotoxicity<sup>[3,8,9]</sup>. In the present study, meloxicam as one of selective COX 2 inhibitor was administered orally to mice to investigate how could affect hepatic tissue at therapeutic doses.

There was a group of histopathological changes observed in livers of treated mice and that is because of the highest tissue concentration of meloxicam were found in liver and kidney after oral meloxicam administration (1mg/kg of meloxicam for 5 days)<sup>[3]</sup>.

Results showed congestion of both blood sinusoids and portal veins as well as dilatation of sinusoidal lumens. These changes may due to impairment of hepatic blood flow caused by portal vein occlusive disorders<sup>[12]</sup>. While, other researches by Ebiad and Lacroix who found that oxicam derivatives may impaired liver function, which interferes with plasma protein metabolism causing reduced blood osmotic pressure with subsequent leakage of fluids, explaining vasoconstriction and vasodilatation in liver parenchyma<sup>[13,14]</sup>.

The present study also showed degenerative changes in hepatic tissue especially hepatocytes that appeared with vacuolated cytoplasm and pyknotic nucleus. In addition, vacuolations of liver cells appeared with more extensive degree in periportal zone (zone I & II) than in the zone 3 surrounding the central veins. PAS stained sections showed that there was a marked depletion in glycogen contents in the periportal area over than other areas. These degenerative lesions might be due to decrease of ATP energy synthesis from liver mitochondria. This concept was reinforced

by previous study in the rat who conducted that salicylic acids triggers mitochondrial dysfunction causing marked fall in ATP which in turn leads to lethal damage and hepatocellular injury<sup>[8,10,15]</sup>. Durham et al were reported that vacuolar degeneration appeared to be alteration produced to collect injurious substances in affected cells<sup>[16]</sup>. While others suggested that these changes were a result of mitochondrial injury and oxidative stress induced by formation of reactive metabolites of drugs<sup>[8,10,17]</sup>. The majority of previous researches were in agreement with the present study. Presence of vacuolations with marked degree in the periportal area may due to the direction of lobular blood supply that means carrying high amount of toxic materials towards nearest areas and extended gradually towards the center. This was also noted by other investigators who used piroxicam in treating mice<sup>[13,16]</sup>.

Liver tissue of treated mice showed area with focal loss of normal hepatic architecture, as well as necrotic and hemorrhagic areas. This may due to deleterious toxic effect of drug metabolites, since meloxicam being metabolized through oxidation in liver<sup>[4,8,17]</sup>. These changes were documented by some authors who found that piroxicam and lumiracoxib caused clinical and histological evidence of massive and sub-massive necrosis<sup>[10]</sup>. Moreover, COX-2 inhibitor drugs might cause liver damage through prostaglandin pathways<sup>[10]</sup>. Regarding to this concept inhibition of PE2 which is vasodilator resulting in overwhelming vasoconstriction leads to rupture blood vessels with subsequently interstitial hemorrhage. Presence of focal degenerative areas without mononuclear cell infiltration in the present study is most probably indication of apoptosis. This might be result of decreased prostaglandin which was found to be anti-apoptotic mitochondrial activity<sup>[10]</sup>, so absence of prostaglandin would induce mitochondrial apoptosis. However, further techniques such as immune-histochemistry are required to demonstrate if there is down regulation of mitochondrial protein BCL2<sup>[10]</sup>.

Last manifestation was the presence of mild infiltration of mononuclear cells in the hepatic tissue. Indicating of the body defense mechanism initiated inflammatory cascades against pathological changes and it may contributes pathogenesis of NSAIDS<sup>[13,17]</sup>.

### Conclusion

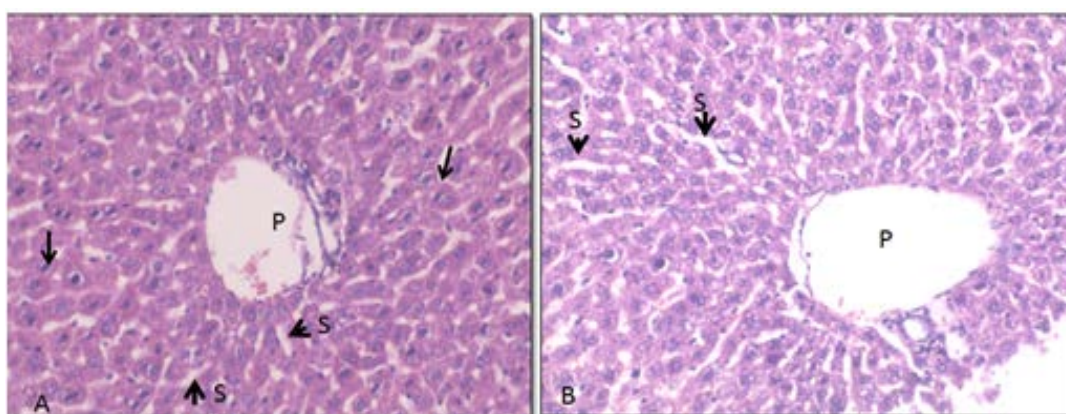
It could be concluded from the present study that meloxicam might cause mild to moderate hepatotoxicity at therapeutic doses level. However, further researches should be carried out to examine if the toxic effects of meloxicam are reversible or not.

### References

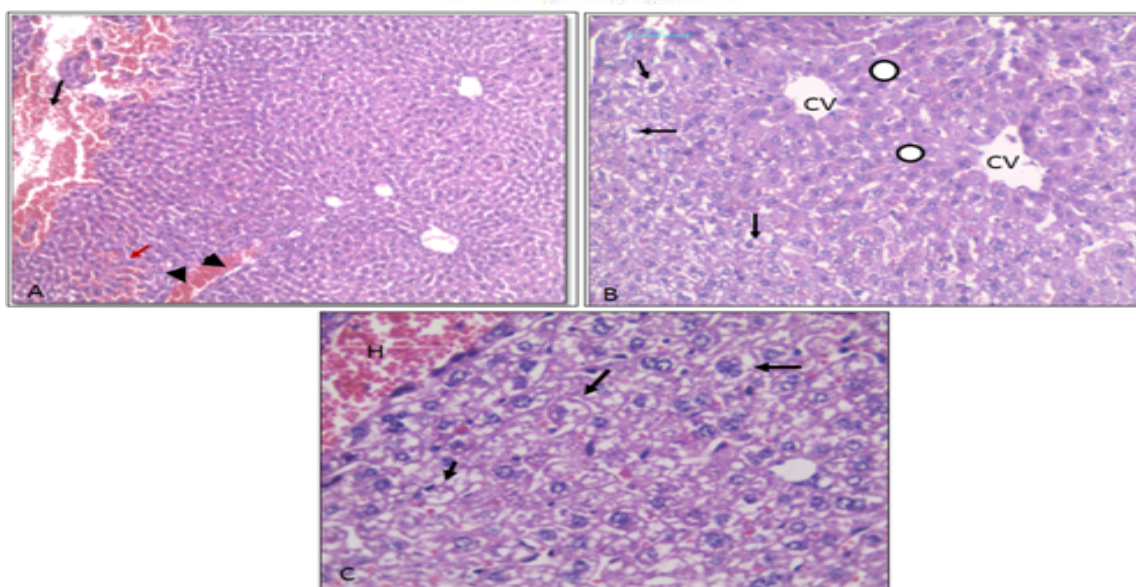
1. Mahmoud, F.Y., Abou-Alghait A.T., Rateb, A., Esam, S. (2010). Comparative study on the effect of long-term administration of non-steroidal anti-inflammatory drugs meloxicam and ketoprofen on the structure of the kidney and gastric mucosa in adult albino rats. *Egypt J Histol* .33:722-734.
2. Andalib, S., Naeinin, A.M., Gajani, A., Asl, N.A., Abdollahi, A. A. (2011). Comparative study pertaining to deleterious effects of diclofenac sodium and meloxicam on kidney tissue in rats. *Excli Journal*.10:149-154.
3. Al-Rekabi, F., Abbas, D., Hadi, N. (2009). Effects of subchronic exposure to meloxicam on some hematological, biochemical and liver histopathological parameters in rats. *Iraqi Journal of Veterinary Sciences*.23:249-254.
4. Ahmed, M.Y., Abdul-Fattah, J.H., Aziz, F.M. (2015). The protective role of vitamin C against the hepatotoxic and nephrotoxic effect of meloxicam in male mice. *Journal of Pharmacy and Biological Sciences*. 10(5):69-73.
5. Ricciotti, E., Garret, A., Gerald, F. (2011). Prostaglandin and inflammation. *Arterioscler Thromb Vasc Biol*. 31(5): 986-1000.
6. Weir, M. (2002). Renal effects of nonselective NSAIDs and coxibs. *Cleve Clin J Medicine*. 69(1):53-58.
7. Modi, G., Mody, S., Patl, H., Dudhatra, G., Kumar, A., Avale, M. (2012). Toxicopathological overview of analgesic and anti-inflammatory drugs in animals. *Journal of Applied Pharmaceutical Science*. 2 (1): 149-157.
8. O'Connor, N., Dragan, P.I., Jones, A.L (2003). Hepatocellular damage from non-steroidal anti-inflammatory drugs. *Q J Med*. 96:787-791.
9. Bjorkman, D (1998). Non-steroidal anti-inflammatory drugs associated to toxicity of the liver, lower gastrointestinal tract and the esophagus. *AM J Med*.105:17-21.
10. Fernando, B. (2010). Non-steroidal anti-inflammatory drugs? What is the actual risk of liver damage? *World J Gastroenterol*. 7; 16(45):6515-6561.
11. Maddrey, W.C., Maurath, C.J., Verburg, K.M., et al. (2000). Hepatic safety and tolerability of the novel cyclooxygenase -2 inhibitor celecoxib. *Am J Ther*.7:153-8.
12. Kumar, V., Abbas, A., Aster, J. (2014). Pathological basis of disease. 9th edition. *Elsevier Inc*.7:153-8.
13. Ebaid, H., Dkhil, M.A., Danfour, M.A., Tohamy, A., Gabry, M.S. Piroxicam induced hepatic and renal histopathological changes in mice. *Libyan J Med*. 82-89.
14. Lacroix, L., Lapeyre-Mestre, M., Bagheri, H., Pathak, A., Montastruc, J.L. (2004). Non-steroidal anti-inflammatory drug induced liver



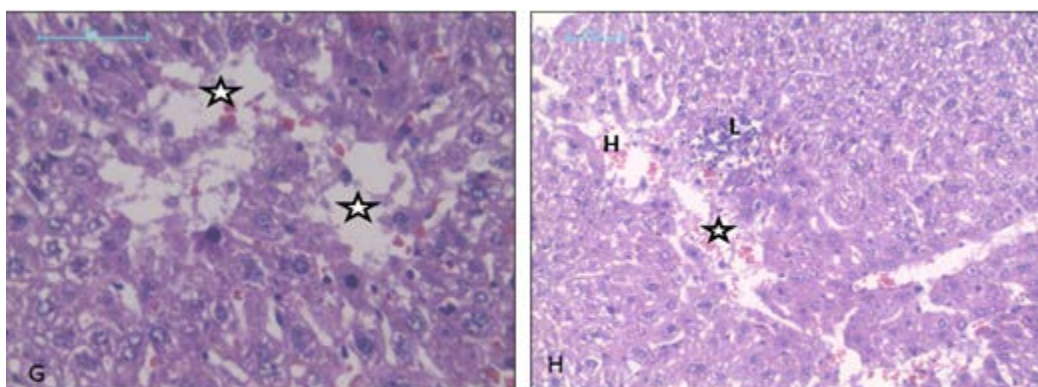
- injury: a case-control study in primary care. *Fundam Clin Pharmacol*.18 (2):201-206.
15. Smochit, N., Sanata, F., Gan, E.H., Sharin, I.A., Zurinia, A. (2004). Liver injury induced by the non-steroidal anti-inflammatory drugs mefenamic acid. *Singapore Med J*. 45 (11):530-532.
  16. Durham, S.K., Brouer, A., Barelds, R.J. (1990). Comparative endotoxin-induced hepatic injury in young and aged rats. *J Pathol*.162:341-349.
  17. Burukoglu, D., Bayu, C., Taplamacioglu, F., Sahin, E., Bektur, E. (2014). Effects of non-steroidal anti-inflammatory meloxicam on stomach, kidney and liver of rats. *Toxicology and Industrial Health*.1-7.



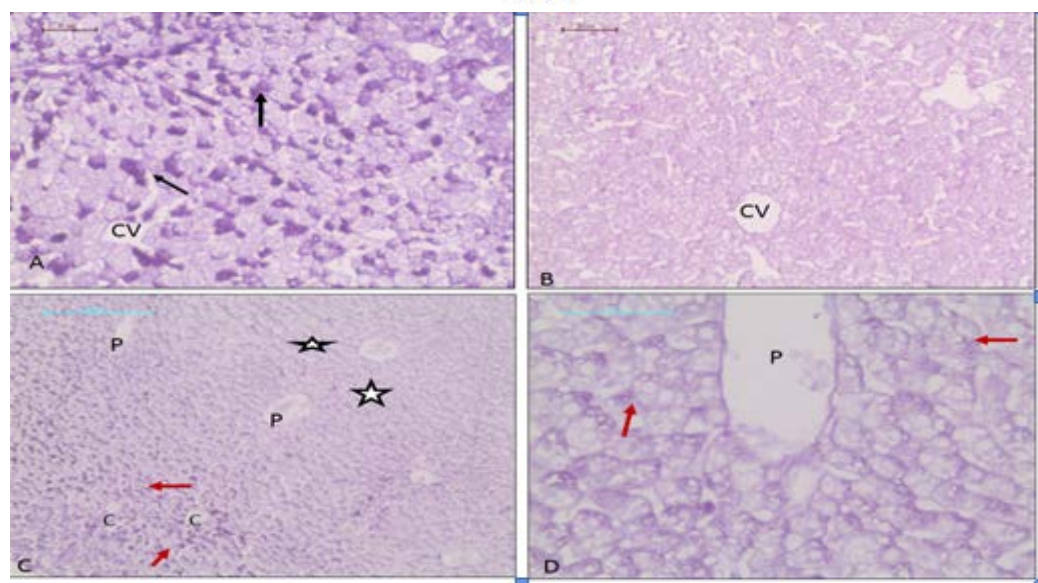
**Fig. 1: Light micrographs of liver mice. A. Liver of control group showing normal architecture, portal area (P) with surrounding hepatocytes (arrow) and normal sinusoidal lumens (S). B Liver of meloxicam treated mice showing dilation of blood sinusoids. Mic Mag x200 (A, B) H&E.**



**Fig. 2: Liver sections from meloxicam treated mice showing: A congestion of both portal veins (arrow head) and blood sinusoids (red arrow), and areas of hemorrhage (black arrow). B The zone III around central vein appeared quite normal (circle) while, zones I & II (periportal areas) showed vacuolations and degeneration of hepatocytes (arrow). C a higher magnification of B in which hepatocytes showed highly vacuolated cytoplasm and pyknotic nuclei as well as loss of normal architecture (arrow). Mic Mag x100(A) x200(B) x400 (C) H&E**



**Fig. 3:** Light micrographs of liver mice treated with meloxicam showing: (G) focal areas of hepatic necrosis without mononuclear cell infiltration (star). (H). mononuclear cellular infiltration (L), necrotic (star) and hemorrhagic areas (H). Mic Mig x400 (G) x200 (H) H&E.



**Fig. 4:** Light micrographs of liver from mice stained with PAS showing: A positive control liver appeared with apparent normal amount of glycogen, intense red color inside hepatocytes (arrow). B negative control section (treated with diastase) appeared without glycogen content. C moderate decrease in glycogen contents in periportal areas (zones I & II) (star), while around central vein (zone III) are quite normal (red arrow). D a higher magnification of C demonstrate depletion of glycogen inside hepatocytes (red arrow). Mic Meg x200(A&B) x100(C) x400 (D). PAS.

#### How to cite this article

Najat M. H. Mohammed, Ezzat El-Drieny, Ibrahim S. El-Drussi, Masouda Al-agory and Ebtesam M. M. Gheth (2019). Histopathological Changes in liver tissue induced by meloxicam in male mice, *Int. J. Pharm. Life Sci.*, 10(1):6059-6063.

Source of Support: Nil; Conflict of Interest: None declared

**Received: 11.12.18; Revised: 21.12.18; Accepted: 20.01.19**

© Sakun Publishing House (SPH): IJPLS

6063